Original Investigation

Indications and Outcomes for Use of Montgomery Cannulas

Semirra Bayan, MD; Henry T. Hoffman, MD, MS

IMPORTANCE To our knowledge, we report the first series to analyze use of the Montgomery cannula as an airway management tool for indications other than obstructive sleep apnea.

OBJECTIVES To analyze the use and outcomes of Montgomery cannula placement for airway management and to identify indications for placement.

DESIGN, SETTING, AND PARTICIPANTS Retrospective review of 20 patients who received a Montgomery cannula from 2003 through 2012 at the University of Iowa Hospitals and Clinics.

INTERVENTION Montgomery cannula placement.

MAIN OUTCOMES AND MEASURES Indications for cannula placement, comorbidities, body mass index, reasons for failure of cannula use, and complications.

RESULTS Indications included glottic stenosis (n = 7), obstructive sleep apnea (n = 5), bilateral vocal cord paralysis (n = 4), subglottic stenosis (n = 4), supraglottic swelling after radiation or chemoradiation therapy (n = 4), bulbar dystonia with paradoxical vocal cord motion (n = 1), vocal cord fixation secondary to rheumatoid arthritis and gastroesophageal reflux disease (n = 1), and airway obstruction associated with seizure disorder (n = 1). Comorbidities included obesity or overweight (n = 14), gastroesophageal reflux disease (n = 9), hypertension (n = 7), and diabetes mellitus (n = 6). Fifteen patients successfully used a Montgomery cannula, including all patients with 3 or fewer comorbidities. Five patients required replacement with a Jackson tracheostomy tube due to persistent tracheostomal granulation tissue (n = 2), feeling safer with the tracheostomy tube (n = 1), a posterior scar band causing airway obstruction (n = 1), and inability to care for the cannula because of poor manual dexterity from arthritis (n = 1). The mean (range) body mass index of successful and unsuccessful users was 27.5 (18.2-37.7) and 33.8 (24.1-42.7), respectively. Complications included the cannula being blocked by adipose tissue (n = 2) or pushed posteriorly into the airway (n = 2). The Montgomery cannula was used as a successful decannulation tool in 4 patients—with the cannula serving as an interim airway management tool leading to tracheostome closure.

CONCLUSIONS AND RELEVANCE We identified features associated with successful use of the cannula and an additional indication for a Montgomery cannula as a step-down management tool for decannulation.

JAMA Otolaryngol Head Neck Surg. 2015;141(2):142-147. doi:10.1001/jamaoto.2014.3079
Published online December 11, 2014.

Author Affiliations: Department of Otolaryngology–Head and Neck Surgery, University of Iowa Hospitals and Clinics, Iowa City, Iowa.

Corresponding Author: Semirra Bayan, MD, Department of Otolaryngology–Head and Neck Surgery, University of Iowa Hospitals and Clinics, 200 Hawkins Dr, Iowa City, IA 52242-1078 (semirra-bayan@uiowa.edu).

Copyright 2015 American Medical Association. All rights reserved.

Downloaded from jamanetwork.com by Comenius University in Bratislava, Alexandra Mikušiaková on 05/23/2025

The silicone tracheal cannula, also known as a Montgomery cannula, was first introduced in 1978.[1-3] It is composed of an inner flange shaped to fit against the anterior tracheal wall and an outer shaft with circumferential ridges that secure a face plate or ring washer in place against the anterior cervical skin (**Figure 1**). The standard maintenance tracheostomy tube used at our institution for long-term use in adult patients who do not require positive-pressure ventilation is the Jackson metal nonfenestrated tracheostomy tube, ranging in size from No. 4 to No. 8. Advantages of the Montgomery cannula favoring its use over this standard tracheostomy tube include the lack of an intraluminal projection into the airway (**Figure 2**), its lower profile, and, in most cases, improved ease of care. Indications for Montgomery cannula placement as first described by Montgomery[1] included sleep apnea, bilateral vocal cord paralysis, laryngeal carcinoma with glottic insufficiency during radiotherapy, chronic lung disease necessitating suctioning, and intermittent laryngeal insufficiency (secondary to neurologic disorders, arthritis, trauma).

Several studies have investigated the success of Montgomery cannula use in the management of obstructive sleep apnea (OSA) and found it to be a useful alternative to a standard tracheostomy tube for that purpose.[4-6] To our knowledge, there are no published series to date that have evaluated Montgomery cannula use in other patient populations. This study evaluates patients with tracheostomy managed with a Montgomery cannula in order to analyze its use for conditions other than OSA and to define limitations to its use.

Methods

The study was conducted under the approval of the institutional review board at the University of Iowa Hospitals and Clinics. Informed consent was waived due to the retrospective nature of the study. Patients receiving Montgomery cannulas were identified through clinic and operating room nursing lists supplemented by active review of patients seen through follow-up in the clinic (H.T.H.) during the course of data retrieval. A medical record review was performed retrospectively on patients who had a Montgomery cannula inserted at any time from 2003 through 2012.

It is our protocol to ensure that the tracheostome is mature and free of granulation tissue before placing a Montgomery cannula. Although the Montgomery cannula can be placed using a tracheal trephine fenestrator at the initiation of tracheostomy, our practice is to initially perform a traditional tracheostomy followed by placement of a cuffed plastic tracheostomy tube and, if the patient is not ventilator dependent, to replace it with a metal nonfenestrated Jackson tracheostomy tube 4 to 7 days postoperatively.[1] Each patient in our series used a standard tracheostomy tube before a Montgomery cannula was placed in either the operating room or the clinic setting. This practice was used to avoid chances of immediate postoperative airway obstruction secondary to the presence of granulation tissue. Corking of the cannulas was dependent on the airway status of the patient. For those dependent on the cannula only at night (patients with OSA) or who were progressing toward decannulation, corking was used during the daytime. Otherwise, patients left the cannulas uncorked and used a speaking valve. Patients are encouraged to clean the cannula twice daily. Cannulas are normally changed by the physician in the clinic every 3 to 4 months, although patients can be taught to change their own cannulas.

Exclusion criteria for use of a Montgomery cannula included the patient factors of unfavorable anatomic features, poor manual dexterity (ie, anticipated trouble cleaning and manipulating the cannula), impaired intellectual capacity, and an inability to care for the Montgomery cannula. Patients who were 100% dependent on the tracheostomy for their airway were also excluded from using a Montgomery cannula. This concept was based on the anticipation that a patient with a moderately compromised airway would be able to breathe long enough to replace the Montgomery cannula with a Jackson tracheostomy tube should the airway become compromised as a result of Montgomery cannula obstruction or dislodgement.

Patient variables and outcomes were analyzed with an emphasis on factors identified as likely to affect the success of the intervention. These variables included body mass index (BMI, calculated as weight in kilograms divided by height in meters squared), medical comorbidities, indications for Montgomery cannula use, recorded reasons for cannula failure, and complications.

Results

Records were retrospectively evaluated. Twenty patients received a Montgomery cannula from 2003 through 2012 at the University of Iowa Department of Otolaryngology-Head and Neck Surgery. Patients who received a Montgomery cannula had a mean (range) age of 58.3 (23-75) years at the time of placement. Use of a Montgomery cannula was established as successful either by decannulation following use of a Montgom-

Figure 1. Montgomery Cannula With Face Plate

Example of an external view of a Montgomery cannula in place with a face plate located at the base of the cannula.

Copyright 2015 American Medical Association. All rights reserved.

Downloaded from jamanetwork.com by Comenius University in Bratislava, Alexandra Mikušiaková on 05/23/2025

ery cannula or by maintaining active use of the cannula at the time of data collection. The "short-term" Montgomery cannulas, with external ring projections extending the length of the tube, were utilized for long-term use. Sixteen patients used a No. 8 short-term Montgomery cannula, 2 patients used a No. 10 short-term Montgomery cannula, and 2 patients used a No. 6 short-term Montgomery cannula.

Duration of Successful Cannula Use

Fifteen patients were classified as successful users of the Montgomery cannula. Among these 15 patients, 11 still had their Montgomery cannulas in place at the time of the conclusion of the present study. Four patients were successfully decannulated—with the Montgomery cannula serving as an interim airway management tool leading to tracheostome closure (**Table**). Patients who were decannulated either passed a sleep study with capping trial or had favorable pulmonary function study results, with adequate peak inspiratory flow prior to decannulation.[7]

Patients who had a Montgomery cannula in place at the time of closure of the study had a mean of 51.5 months (4.3 years) of success with cannula placement. The longest period of successful Montgomery cannula use was 11.3 years. Decannulated patients had maintained their Montgomery cannula for a mean of 30.8 months (2.6 years) before decannulation and tracheostome closure (Table).

Montgomery Cannula Replacement With Tracheostomy Tube

Permanent Replacement

Of the 20 patients evaluated, 5 had their Montgomery cannula permanently removed and replaced with a Jackson tracheostomy tube (Table). Reasons for cannula removal included presence of tracheostomal granulation tissue (n = 2), patient reporting a greater sense of safety with the Jackson tracheostomy tube (n = 1), unfavorable anatomic feature identified as a posterior scar band causing an airway obstruction not adequately bypassed by the cannula (n = 1), and inability to care for the cannula because of manual dexterity issues from rheumatoid arthritis (n = 1) (Table). In this group who were ultimately unable to tolerate use of the Montgomery cannula, the mean length of time that the Montgomery cannula was in place before removal was 1.4 months (Table).

Intermittent Removal

Five patients had intermittent success with the Montgomery cannula. Reasons included tracheostomal granulation tissue removal (n = 2), Montgomery cannula displacement (n = 2), and cellulitis (n = 1). One patient experienced 3 separate episodes of granulation tissue removal. Cannula replacement after granulation tissue removal occurred anywhere from 1 to 8 months after debridement. In the 2 patients whose Montgomery cannula became dislodged, the cannula was replaced the day of the incident.

Indications for Montgomery Cannula Placement

Indications for Montgomery cannula placement included glottic stenosis (n = 7), OSA (n = 5), bilateral vocal cord paralysis (n = 4), subglottic stenosis (n = 4), supraglottic swelling after radiation or chemoradiation therapy (n = 4), bulbar dystonia with paradoxical vocal cord motion (n = 1), vocal cord fixation secondary to arthritis and gastroesophageal reflux disease (n = 1), and seizure disorder-associated airway obstruction during seizure activity (n = 1). Five patients had multiple indications for Montgomery cannula placement (Table).

Patients with subglottic stenosis or OSA were more likely to be unable to tolerate use of the Montgomery cannula compared with those with other indications. Two of the 4 patients with subglottic stenosis and 3 of the 5 patients with OSA

Figure 2. View of the Airway With Montgomery Cannula vs Standard Tracheostomy Tube

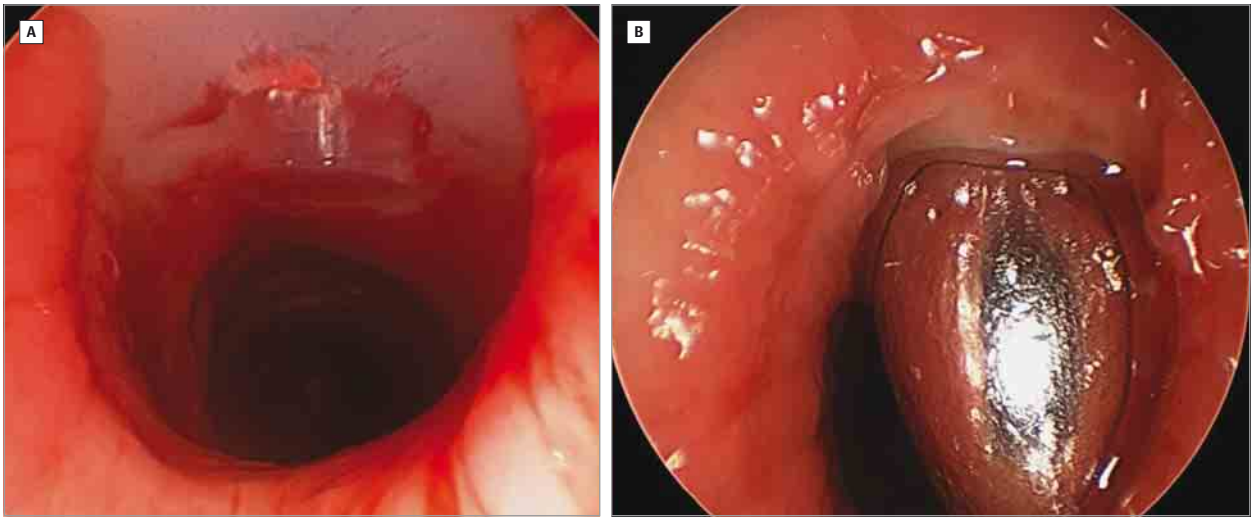

A, This view demonstrates the inner flanges of the Montgomery cannula resting against the anterior tracheal wall with a clear view to the carina. B, The same airway with a tracheostomy tube in place.

Copyright 2015 American Medical Association. All rights reserved.

Downloaded from jamanetwork.com by Comenius University in Bratislava, Alexandra Mikušiaková on 05/23/2025

Table. Body Mass Index (BMI), Indication, Outcome, Duration of Montgomery Cannula Use, and Reason for Replacement With Jackson Tracheostomy Tube for Each Patient

Patient No.	BMI[a]	Indication for Placement	Duration		Reason for Failure
			mo	y	
Cannula Currently in Place					
4	20.5	Glottic stenosis	10	0.8	...
5	26.3	Glottic stenosis	96	8.0	...
6	22.2	Bilateral vocal cord paralysis	76	6.3	...
8	25.8	Bilateral vocal cord paralysis	108	9.0	...
10	18.2	Bilateral vocal cord paralysis	136	11.3	...
13	26.3	Supraglottic swelling after radiation therapy; OSA	16	1.3	...
15	37.7	Bulbar dystonia with paradoxical vocal cord motion	6	0.5	...
16	34.0	Subglottic stenosis	10	0.8	...
17	30.0	Seizure disorder	85	7.1	...
19	24.6	Glottic stenosis	10	0.8	...
20	33.4	Glottic stenosis	13	1.1	...
Decannulated					
3	31.3	Subglottic stenosis	9	0.7	...
7	27.4	Glottic stenosis	88	7.3	...
12	32.5	Supraglottic swelling after radiation therapy; OSA	11	0.9	...
14	22.4	Glottic stenosis	15	1.2	...
Cannula Removed					
1	32.3	Supraglottic swelling after radiation therapy	2	0.2	Increased patient-perceived security with Jackson tracheostomy
2	24.1	Glottic stenosis; subglottic stenosis	0.2	0.02	Scar band
9	35.6	Subglottic stenosis; bilateral vocal cord paralysis; OSA	0.3	0.02	Granulation tissue
11	34.4	Supraglottic swelling after radiation therapy; OSA	4	0.3	Impaired manual dexterity secondary to rheumatoid arthritis
18	42.7	OSA; vocal cord fixation secondary to rheumatoid arthritis	0.3	0.02	Granulation tissue

Abbreviations: ellipses, not applicable; OSA, obstructive sleep apnea.

[a] Calculated as weight in kilograms divided by height in meters squared.

required replacement of the Montgomery cannula with a Jackson tracheostomy tube.

BMI

Patients' mean (range) BMI at the time of tracheostomy was 29.1 (18.2-42.7). The mean BMI of patients who were considered successful users (either decannulated or still using the Montgomery cannula) was 27.5 (overweight). The mean BMI of patients for whom the Montgomery cannula was removed because of failure of its use was 33.8 (obese). Fourteen of the patients evaluated had a BMI that was considered overweight or obese at the time of tracheostomy. Of the 10 patients who were classified as obese (BMI, ≥30), 4 had been treated with a 4-flap epithelial-lined tracheostomy with anterior cervical lipectomy before placement of the Montgomery cannula. Obese patients who underwent a 4-flap epithelial-lined tracheostomy were more likely to have success with the Montgomery cannula than obese patients who received standard tracheostomy (3 of 4 patients vs 4 of 6 patients, respectively). The single patient with failure of Montgomery cannula use in the epithelial-lined tracheostomy group returned to use of the metal Jackson tracheostomy tube because of a problem with manual dexterity associated with rheumatoid arthritis. The presence of granulation tissue contributed to the removal of the Montgomery cannula in the 2 morbidly obese patients who had a standard tracheostomy.

Medical Comorbidities

The majority of patients in this series had multiple medical comorbidities, including obesity or overweight (n = 14), gastroesophageal reflux disease (n = 9), hypertension (n = 7), and diabetes mellitus (n = 6). Patients with 3 or fewer medical comorbidities had no need for replacement of the cannula with a Jackson tracheostomy tube, compared with patients with more than 4 medical comorbidities who did have a higher rate of cannula replacement.

Complications

Among the patients who maintained use of the Montgomery cannula, 4 complications were recorded. Two patients had difficulties with their cannula being blocked by extra adipose tissue in the breast and submental area, successfully addressed by replacement with a cannula trimmed to a lesser extent (longer cannula). Two patients had their can-

Copyright 2015 American Medical Association. All rights reserved.

Downloaded from jamanetwork.com by Comenius University in Bratislava, Alexandra Mikušiaková on 05/23/2025

nulas pushed posteriorly into the airway. The first patient quickly pulled the cannula forward without complication. The second patient sought care at a local emergency department where lack of familiarity with the Montgomery cannula on the part of local physicians provoked the patient to remove the cannula herself and replace it with a Jackson tracheostomy tube.

Discussion

Although no specific quality of life or patient satisfaction surveys were used in this assessment, the careful recording of patient perception of their experience with the Montgomery cannula compared with the tracheostomy tube permitted the observation that the majority of patients cited ease of cleaning, increased comfort, and the low profile of the Montgomery cannula as reasons for satisfaction with the cannula and desired to continue maintaining the use of the cannula rather than reverting back to the tracheostomy tube.[8] One patient complained that she was upset that she did not know about the Montgomery cannula and was therefore compelled to use the Jackson tube for 6 years before she was successfully outfitted with the Montgomery cannula.

Fifteen patients were considered successful users of their Montgomery cannulas for indications including upper airway swelling secondary to radiation therapy, vocal cord paralysis, subglottic stenosis, glottic stenosis, sleep apnea, vocal cord fixation, seizure disorder causing airway obstruction, and bulbar dystonia with paradoxical vocal cord motion. The presence of granulation tissue was a major factor in cannula removal. It contributed to the outcomes of 2 patients who had their cannulas removed permanently and 2 patients who had the cannula removed intermittently. Granulation tissue was also a major contributor to cannula removal in past studies looking at patients with OSA. Patients in this assessment who had granulation tissue carried a diagnosis of either OSA or subglottic stenosis. The relationship between granulation tissue, subglottic stenosis, and the body habitus associated with OSA may predispose patients to more severe granulation tissue formation sufficient to warrant Montgomery cannula removal. Medical comorbidities caused 1 patient to replace the Montgomery cannula with a Jackson tracheostomy tube as a result of dexterity issues from rheumatoid arthritis, highlighting one of the limitations to keep in mind when considering a patient for a cannula.

Whereas the mean BMI was higher in patients who were ultimately unable to tolerate use of the Montgomery cannula, there did not appear to be a correlation between BMI and successful use of the Montgomery cannula. Ideally, neck circumference would be a superior predictor to BMI. However, neck circumference was not recorded in the patient population and could not be evaluated. It is noteworthy that among the 8 patients classified as obese, 3 of the 4 who underwent a 4-flap epithelial-lined tracheostomy with anterior cervical lipectomy were classified as successes with cannula placement. In contrast, the 2 morbidly obese patients treated via standard tracheostomy (without an epithelial-lined tracheostome) required removal of the Montgomery cannula as a result of the development of granulation tissue. This analysis supports the contention of Strauss[4] that a skin-lined tracheostomy is a useful method of allowing patients whose large neck girth may otherwise give them an unfavorable anatomic configuration for cannula placement an improved chance at successful use of a cannula.[9]

Montgomery cannula use also played a role for several patients in their path toward decannulation, as 4 of the 20 patients were successfully decannulated following interval use of a Montgomery cannula. Patients who have a capped tracheostomy tube may still have difficulties with breathing secondary to airway resistance caused by the intraluminal projection of the tracheostomy tube. In our experience, patients have reported irritation caused by positional movement of the metal tracheostomy tube that impaired sleep in a manner not reported with use of the Montgomery cannula. In addition, decannulation during the study can potentially cause an unwanted obstruction in an unprotected airway for a patient who is not ready for decannulation. We believe that the low profile of a Montgomery cannula and lack of intraluminal projection gives the cannula an advantage over the standard tracheostomy during a sleep study evaluation while still providing a safe airway for the patient, leading to more accurate results (Figure 2).

The most concerning complication of airway obstruction associated with use of the cannula occurred transiently in 2 patients. These patients experienced posterior displacement of the Montgomery cannula into the airway. In both instances, patients were able to retrieve the cannula by pulling it forward. In 1 patient, the lack of familiarity with the cannula on the part of a local emergency department motivated the patient to take action herself and remove the cannula. This reported experience highlights the importance of patient education regarding cannula care and actions to take in potential emergencies.

A short-term Montgomery cannula was used almost exclusively in all 20 patients evaluated for this study, which is a departure from traditional recommendations for Montgomery cannula use in which the short-term cannula is used transiently until the "long-term" cannula is placed. The long-term cannula has a variable length of the barrel without ridges (circular projections). The ridges along the full extent of the short-term cannula help to stabilize the cannula and, in our experience, have not been perceived as contributing to production of granulation tissue. An additional benefit of use of the short-term cannula for all patients is increased simplicity in choosing the length of the cannula because there is a need for the exact cannula measurements for long-term cannulas. It is our overall philosophy to maintain the cannula length, measured as projection from the skin, to be initially long so that if there is a posterior migration, the patient is able to readily grasp the cannula and pull it forward. As the patient becomes more proficient with cannula care, it is then shortened to the patient's desired comfort level. It is our experience that most patients prefer a shorter cannula because it has a lower profile. Only 2 patients requested lengthening of the cannula because adipose tissue was creating an obstruction to the cannula.

Copyright 2015 American Medical Association. All rights reserved.

Downloaded from jamanetwork.com by Comenius University in Bratislava, Alexandra Mikušiaková on 05/23/2025

The components of the Jackson tracheostomy tube, including inner cannula and longer length within the trachea, make it a reliable manner of maintaining an airway. However, often its higher profile makes it less desirable for a select group of patients who are not 100% dependent on their tracheostomy. It is this select patient group that may be considered for Montgomery cannula placement. The high success rate with use of the Montgomery cannula likely reflects careful patient selection and proper patient education. This favorable experience supports our enthusiasm for use of this device in motivated patients with favorable anatomic features. When counseling patients with a compromised airway about management alternatives, we identify the Montgomery cannula as a potential option that appropriately selected patients prefer to the larger standard tracheostomy tube requiring a neck strap. The potential to use this method of airway management can extend to patients with a variety of indications for a tracheostomy who are not 100% tracheostomy dependent.

The largest limitation to this study is the small patient population. Although this study spanned a 9-year period, only 20 patients were identified who met the criteria for use of a Montgomery cannula, highlighting the selective process of choosing the correct patients for cannula placement.

Conclusions

Literature regarding the indications and success with Montgomery cannulas is sparse. Studies to date have focused on the use of the Montgomery cannula for nocturnal airway management in patients with severe OSA. To our knowledge, this is the first study of its kind to analyze the use of Montgomery cannulas for airway management in patients with a variety of indications. We also identified an additional indication for a Montgomery cannula as a step-down management tool for decannulation. Granulation tissue may limit cannula use—further stressing the importance of careful selection of patients who have the ability to care for the cannula. Further evaluation of indications and success with Montgomery cannula use in a larger patient population will help to continue to refine its use in the management of airway obstruction.

ARTICLE INFORMATION

Submitted for Publication: June 21, 2014; final revision received September 27, 2014; accepted October 23, 2014.

Published Online: December 11, 2014. doi:10.1001/jamaoto.2014.3079.

Author Contributions: Both authors had full access to all of the data in the study and take responsibility for the integrity of the data and the accuracy of the data analysis.
Study concept and design: Hoffman.
Acquisition, analysis, or interpretation of data: Both authors.
Drafting of the manuscript: Both authors.
Critical revision of the manuscript for important intellectual content: Hoffman.
Statistical analysis: Bayan.
Administrative, technical, or material support: Hoffman.
Study supervision: Hoffman.

Conflict of Interest Disclosures: None reported.

Previous Presentation: This study was presented as a poster at the American Academy of Otolaryngology–Head and Neck Surgery Annual Meeting; September 29 through October 2, 2013; Vancouver, British Columbia, Canada.

REFERENCES

1. Montgomery WW. Silicone tracheal cannula. *Ann Otol Rhinol Laryngol*. 1980;89(6, pt 1):521-528.

2. Lavelle WG, Montgomery WW, Jacobs EE Jr. Silicone tracheal cannula: update. *Ann Otol Rhinol Laryngol*. 1987;96(4):446-448.

3. Montgomery WW, Montgomery SK. Manual for use of Montgomery laryngeal, tracheal, and esophageal prostheses: update 1990. *Ann Otol Rhinol Laryngol Suppl*. 1990;150:2-28.

4. Strauss M. Use of modified silicone tracheal cannula for obstructive sleep apnea. *Laryngoscope*. 1990;100(2, pt 1):152-154.

5. Fedok FG, Strauss M, Houck JR, Cadieux RJ, Kales A. Further clinical experience with the silicone tracheal cannula in obstructive sleep apnea. *Otolaryngol Head Neck Surg*. 1987;97(3):313-318.

6. Orsini MA, Conner GH, Cadieux RJ, Kales A. Clinical experience with the silicone tracheal cannula in obstructive sleep apnea. *Otolaryngol Head Neck Surg*. 1984;92(2):132-135.

7. Hoffman H. Iowa Head and Neck Protocols: Spirometry - PIF - Peak Inspiratory Flow. December 26, 2010. https://wiki.uiowa.edu/display/protocols/Spirometry+PIF+Peak+Inspiratory+Flow. Accessed December 2, 2012.

8. Hoffman H. Iowa Head and Neck Protocols: Montgomery Cannula Insertion in Clinic. December 5, 2011. https://wiki.uiowa.edu/display/protocols/Montgomery+Canula+insertion+in+clinic. Accessed December 2, 2012.

9. Hoffman H. Iowa Head and Neck Protocols: Epithelial-Lined Tracheostomy (With Anterior Cervical Lipectomy and Thyroid Isthmusectomy). April 8, 2012. https://wiki.uiowa.edu/display/protocols/Four-flap+Epithelial+Lined+Tracheotomy. Accessed December 2, 2012.

Copyright 2015 American Medical Association. All rights reserved.

Downloaded from jamanetwork.com by Comenius University in Bratislava, Alexandra Mikušiaková on 05/23/2025